

Management of Cranial Cruciate Ligament Disease in Dogs

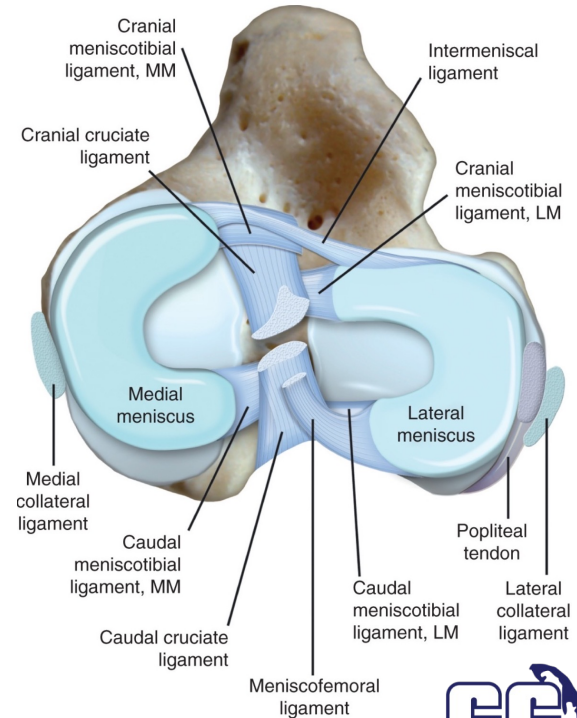
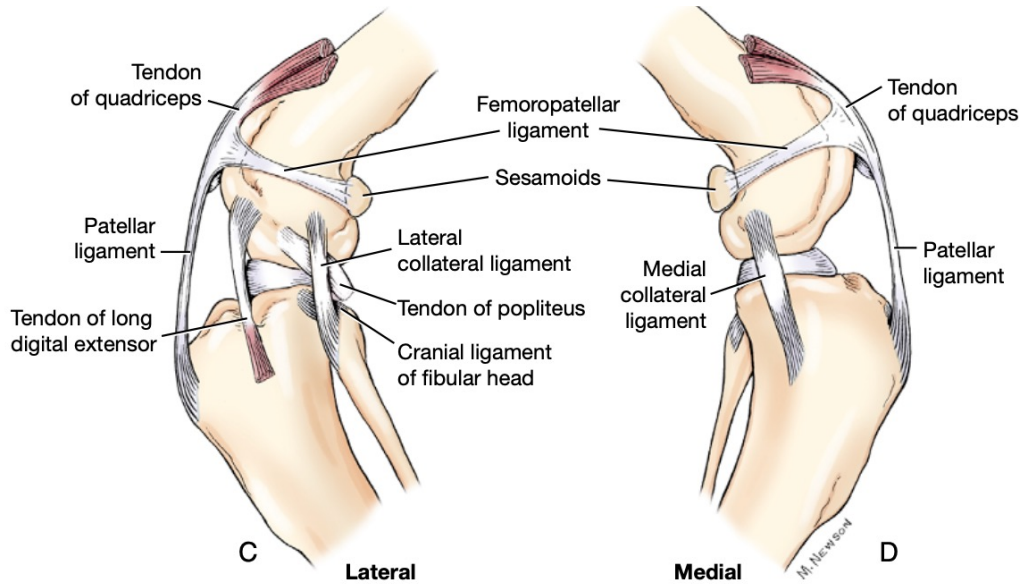
Daniel J. Adams, VMD, DACVS-SA
Surgeon
Cape Cod Veterinary Specialists



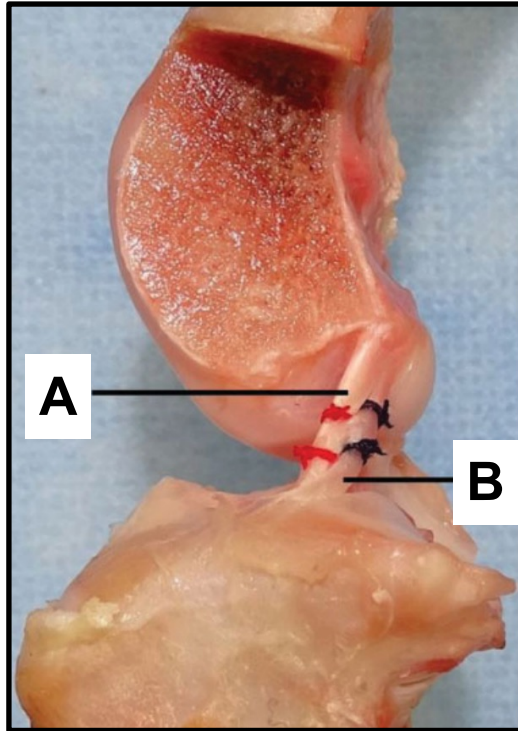
OUTLINE

1. Stifle anatomy
2. Functional anatomy
3. Pathophysiology
4. Patient presentation
5. Diagnosis
6. Treatment options
7. Outcomes and managing client expectations

STIFLE ANATOMY



FUNCTIONAL ANATOMY



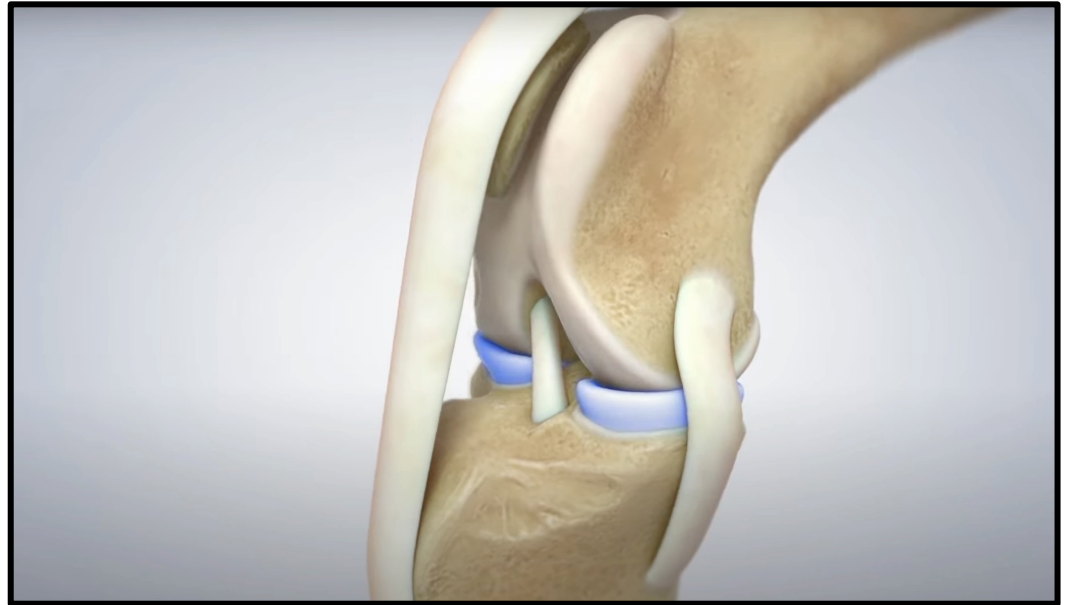
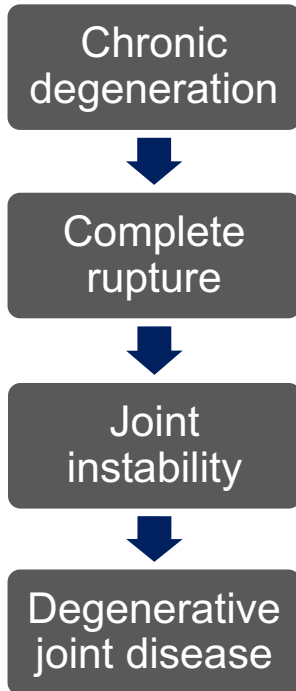
Functions of the CrCL

- Prevent stifle hyperextension
- Prevent internal rotation of tibia
- Prevent cranial tibial subluxation
- Proprioception

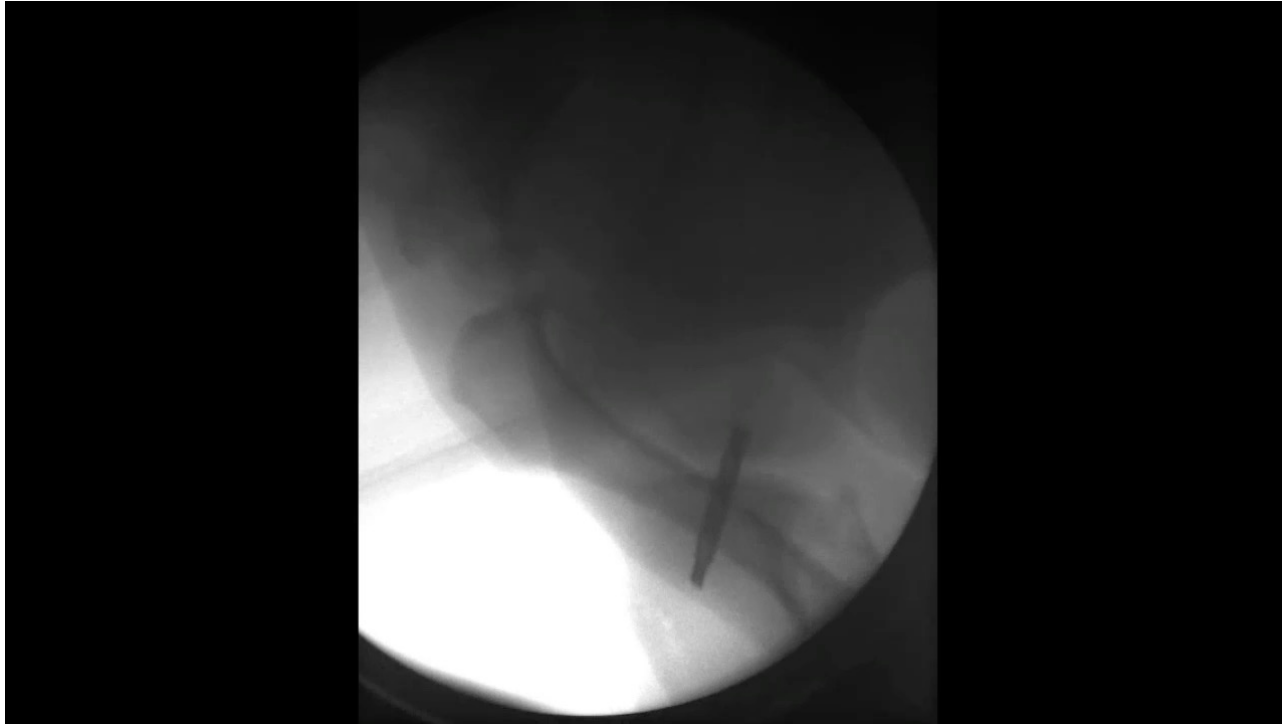Structural divisions

- Craniomedial band (A) – **always taught**
- Caudolateral band (B) – **lax with flexion**

PATHOPHYSIOLOGY



CrCL DEFICIENT STIFLE



PATIENT PRESENTATION

Common clinical signs

- Acute lameness
- Chronic lameness
- Acute on chronic lameness
- Unwillingness to play, go for walks
- Muscle atrophy
- Limited response to analgesics




PHYSICAL EXAMINATION

Common examination findings

- Stifle effusion
- Medial buttress
- Cranial drawer positive
- Tibial thrust positive
- **Pain with stifle extension**



Instability may not be apparent, pain with extension nearly ubiquitous



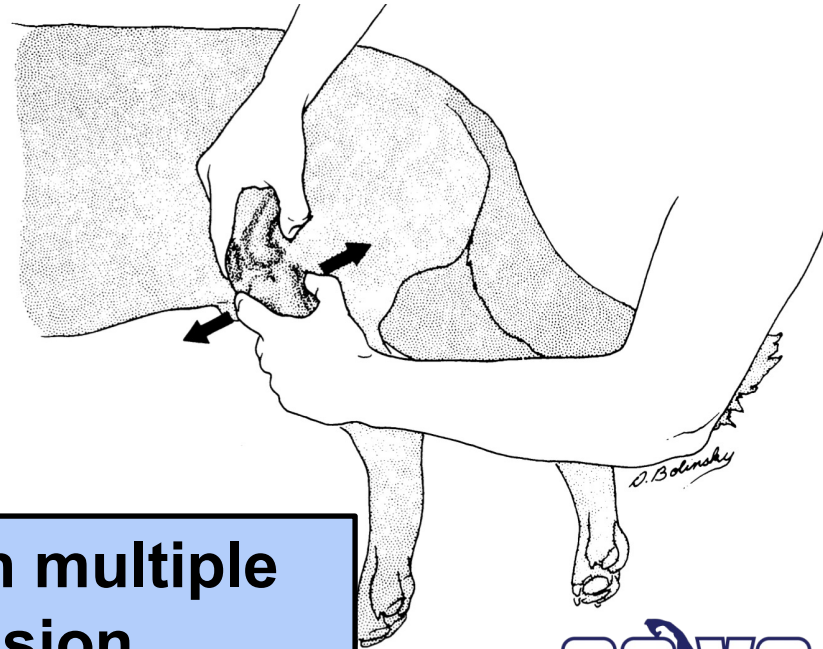
Cranial Drawer Test

Landmarks

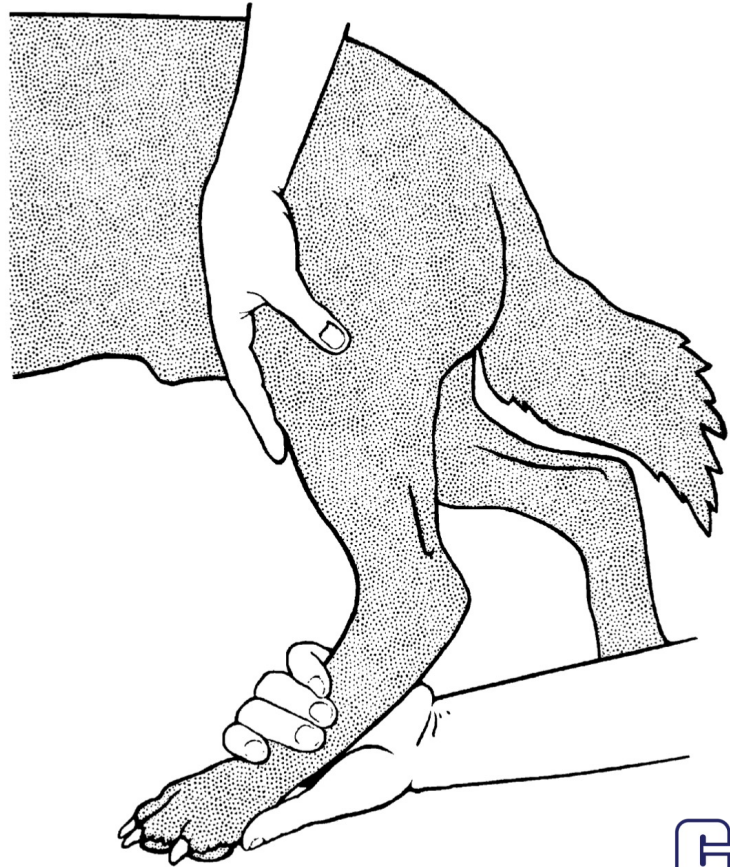
- Lateral fabella
- Patella
- Tibial tuberosity
- Fibular head

Partial vs. complete tear

Check for cranial drawer with multiple degrees of flexion/extension



Tibial Compression Test (*Tibial Thrust*)



A modified tibial compression test for the detection of meniscal injury in dogs

S. VALEN¹, C. McCABE, E. MADDOCK, S. BRIGHT AND B. KEELEY

Northwest Surgeons, Sutton Weaver, Cheshire, WA7 3FW

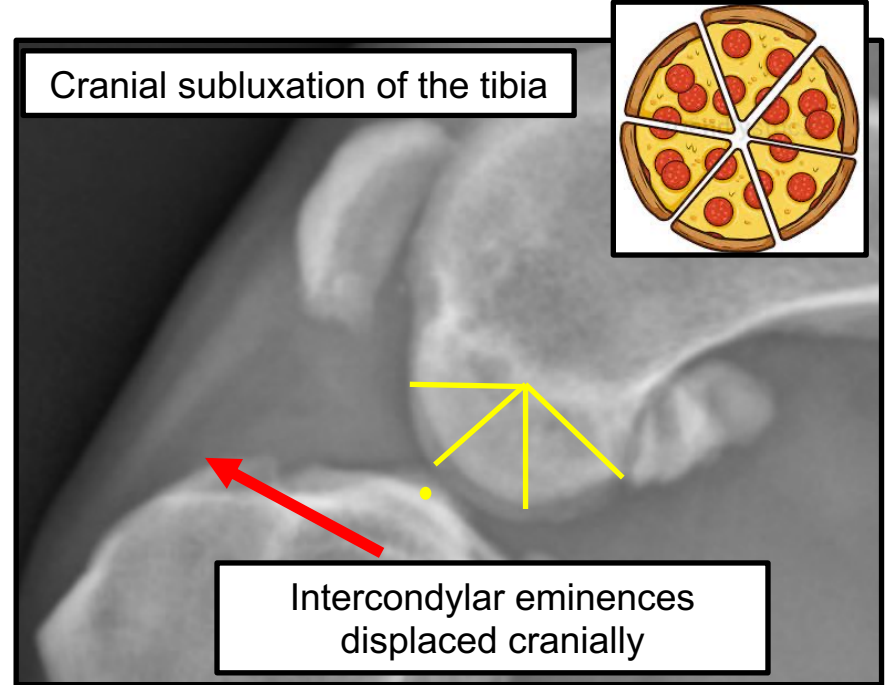
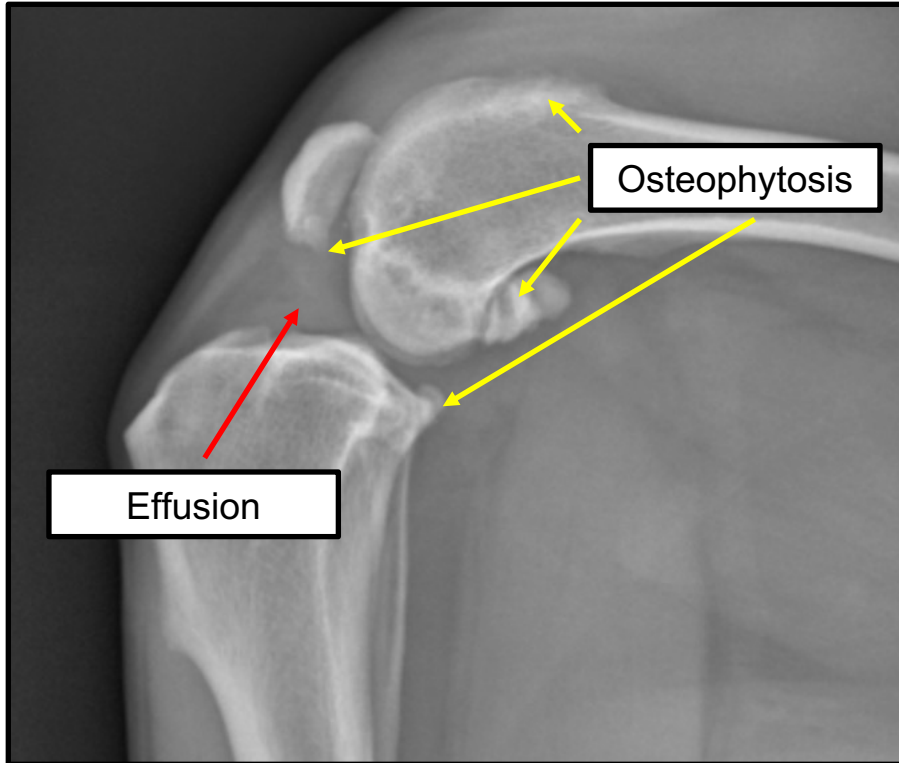
¹Corresponding author email: susanne.valen@hotmail.com

- Meniscal “click”
- Tibial compression test performed with axial loading and full stifle range of motion
- Sensitivity 63% vs 40-50% using conventional exam techniques
- Specificity 77%

DIFFERENTIAL DIAGNOSES

- Isolated meniscal injury – boxers
- Isolated CdCL injury – basset hounds
- Salter-Harris fracture in juvenile dogs – may have "positive" drawer
- Fracture, other ligamentous injury
- Neoplasia
- Septic arthritis
- Immune mediated arthropathies

COMMON RADIOGRAPHIC FINDINGS



TREATMENT OPTIONS



Conservative
Management



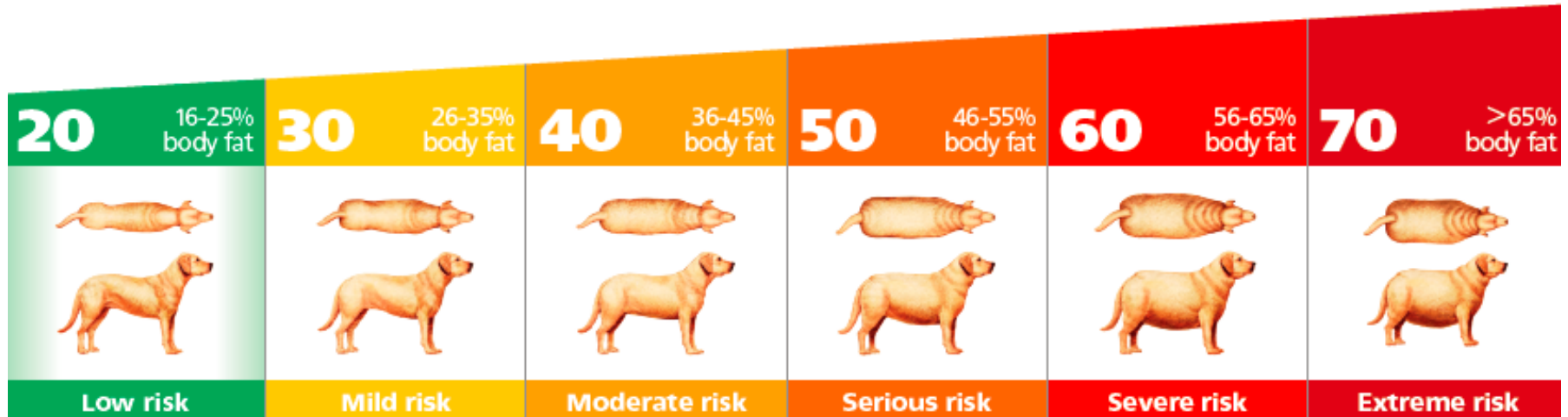Surgical
Management

CONSERVATIVE MANAGEMENT

1. Weight control
2. Exercise modification
3. Diet
4. Drugs
5. Supplements
6. Supportive care

WEIGHT CONTROL

Most important factor of mitigating long term clinical signs of osteoarthritis



Lifelong diet restriction and radiographic evidence of osteoarthritis of the hip joint in dogs

Gail K. Smith, VMD, PhD; Erin R. Paster, DVM; Michelle Y. Powers, DVM; Dennis F. Lawler, DVM; Darryl N. Biery, DVM, DACVR; Frances S. Shofer, PhD; Pamela J. McKelvie, VMD; Richard D. Kealy, PhD

Benefits of lean body weight and calorie restriction

- Later onset of osteoarthritis (6 years)
- Reduced severity of osteoarthritis
- Later and less requirement for analgesics
- Longer life expectancy (2 years)

Exercise Modification



Controlled leash walks



Swimming



Jumping from heights

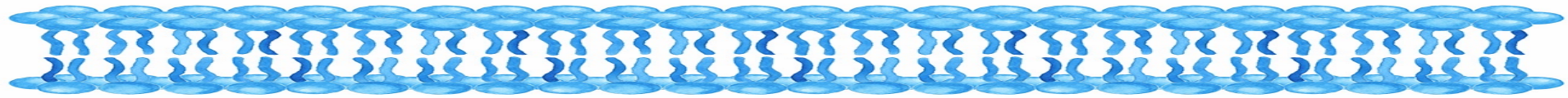
JOINT DIETS

Key ingredients

- High ratio $n-3$: $n-6$ fatty acids
- Chondroitin sulfate
- Glucosamine
- Antioxidants
- Vitamin E
- Hydrolyzed collagen
- Green lipped muscle extract

NB: ingredients variable across brands and formulations





***n*-6 fatty acids**

PLA2

Arachadonic acid

COX, LOX

**Pro-inflammatory
mediators (e.g. PGE2)**

***n*-3 fatty acids**

PLA2

EPA, DHA

COX, LOX

**Anti-inflammatory
mediators**

↑ ***dietary n*-3 : *n*-6
fatty acids**

JOINT DIETS

Current evidence

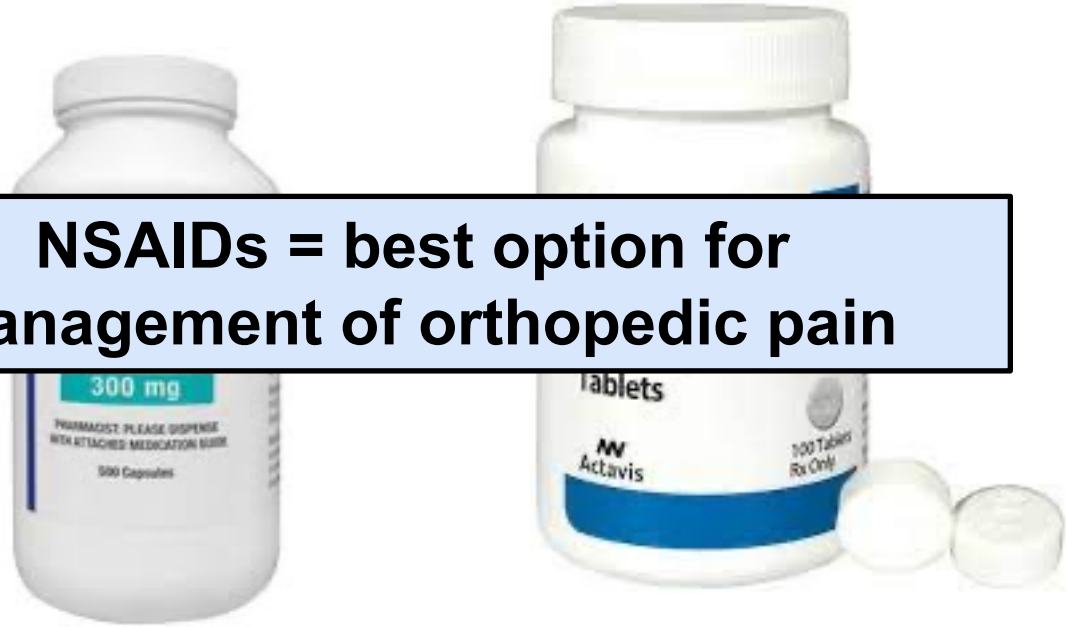- Decreased synovial PGE2
- Increased ground reaction forces
- Decreased OA
- Improved clinical signs of OA per owner assessment
- Decreased synovial PGE2, decreased OA in TPLO patients



DRUGS



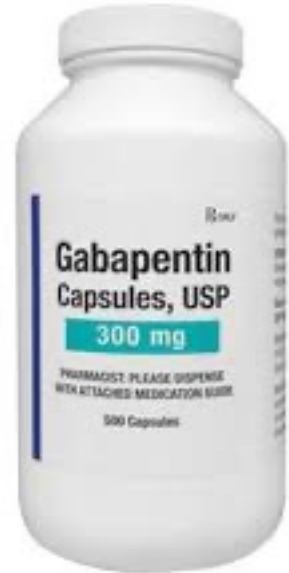NSAIDs = best option for management of orthopedic pain



DRUGS

Gabapentin

- Voltage gated Ca channel blocker
- Improvement in peak vertical force combined with NSAID
- Limited evidence for efficacy
- ...But well tolerated



DRUGS

Amantadine

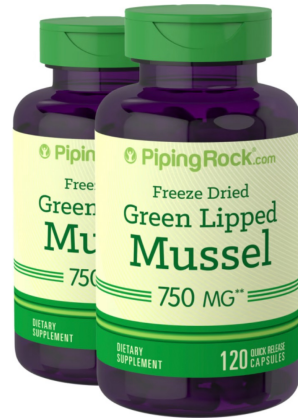- NMDA receptor antagonist
- Treatment of “wind-up” pain
- May take several weeks for response
- GI side effects
- Limited evidence for efficacy
- Synergistic effects with NSAID in cats



What about tramadol?

- Weak μ -receptor agonist
- Very little active metabolite produced during metabolism (dogs)
- No difference in force plate parameters compared to placebo
- **Ineffective for orthopedic pain**

SUPPLEMENTS

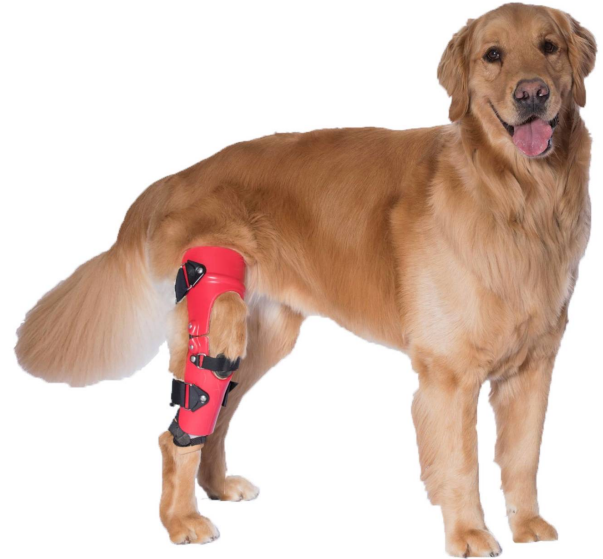

Little supporting evidence, caregiver placebo effect?

ALTERNATIVE TREATMENTS

Orthoses

- Decreases stifle instability
- Skin irritation common
- May not be tolerated
- \$\$\$\$\$ for quality orthosis
- 10% clients eventually pursue surgery




ALTERNATIVE TREATMENTS

Regenerative medicine

- Platelet rich plasma (PRP)
- Possible beneficial effects in early partial CrCL tear?
- Very limited evidence at this time

Platelet Rich Plasma

- Platelet poor plasma
- Platelet rich plasma
- Red blood cells



SURGICAL MANAGEMENT



Is surgery *really* necessary?

Consequences of untreated CrCL disease

- Progression of osteoarthritis
- Persistent lameness
- 2/3 dogs require long term analgesics
- Reduced muscle mass and range of motion
- Meniscal injuries
- Reduced life expectancy

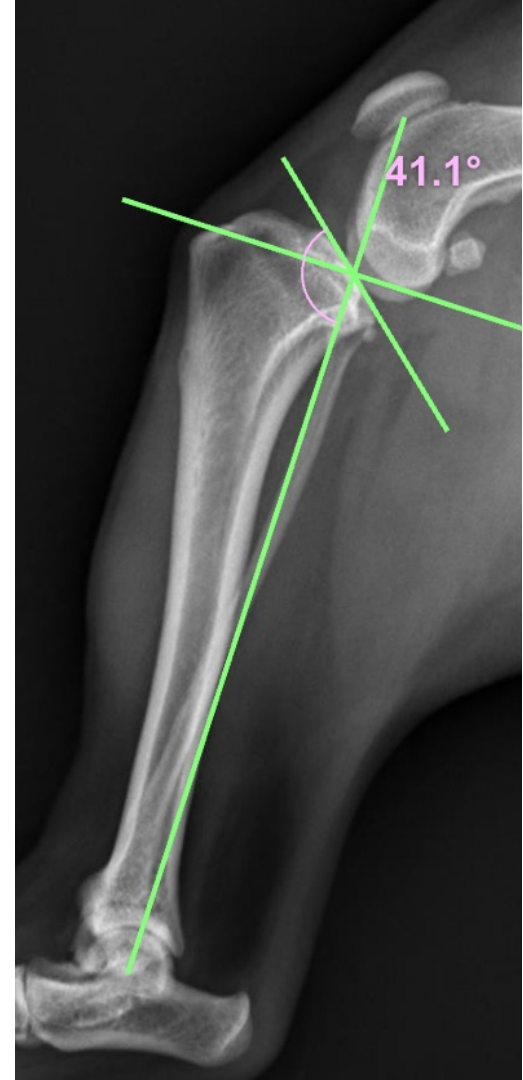


Surgery should be considered for all patients

Do *small* dogs need surgery?

- Favorable outcomes with conservative management previously reported
- Level of evidence weak
- Recovery times longer
- Atrophy, OA, lameness all reported in clinically “normal” dogs

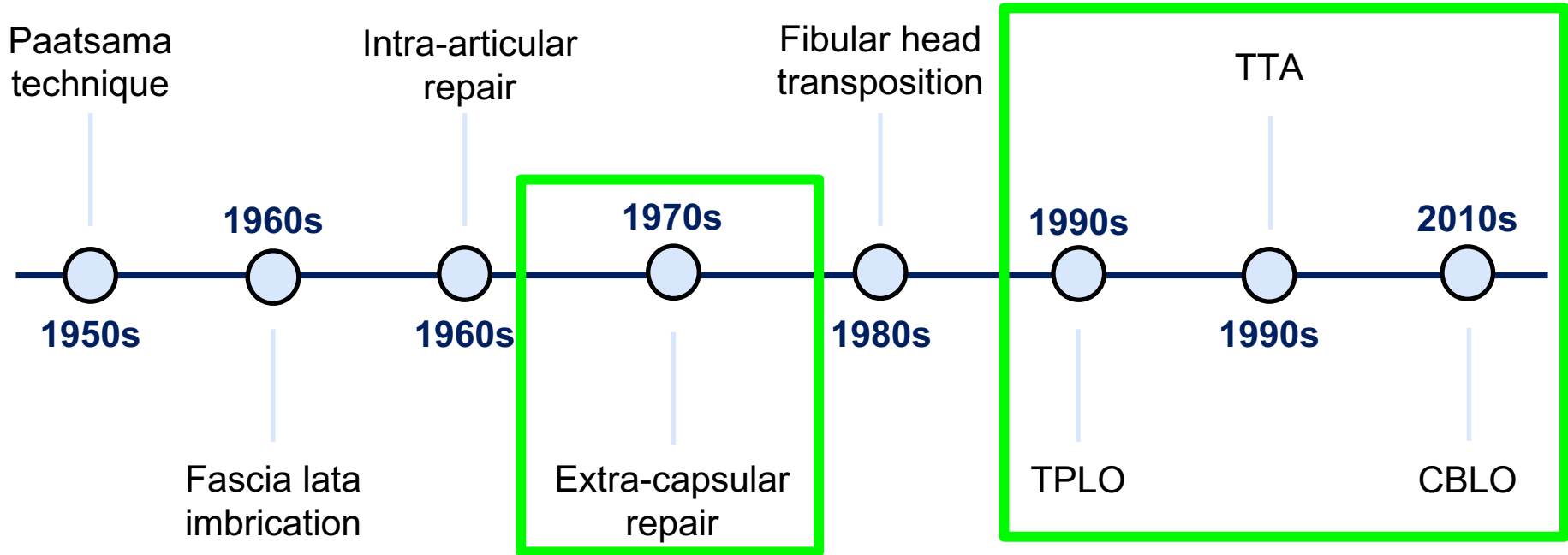
Unique anatomy of small breeds



Do *partial tears* need surgery?

- CrCL does not regenerate or spontaneously heal
- Progressive degeneration likely
- Inflammation, synovitis, OA development
- Early intervention advocated by most

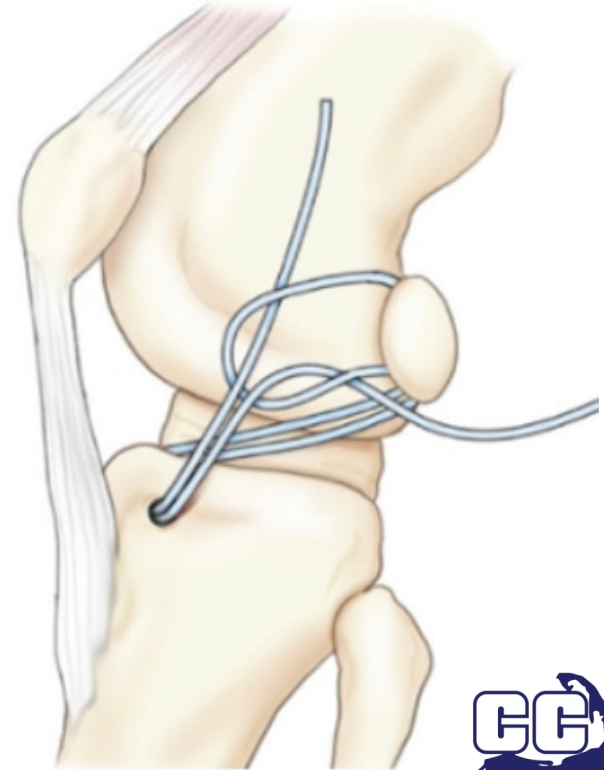
HISTORICAL PERSPECTIVE



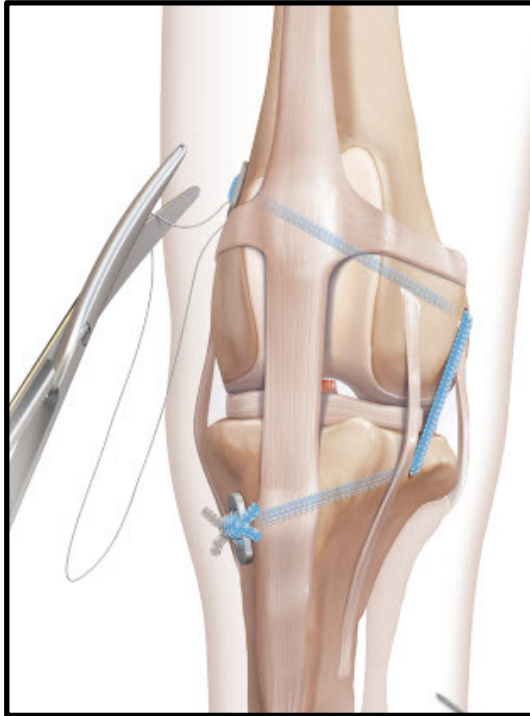
EXTRACAPSULAR REPAIRS

Lateral fabellotibial suture

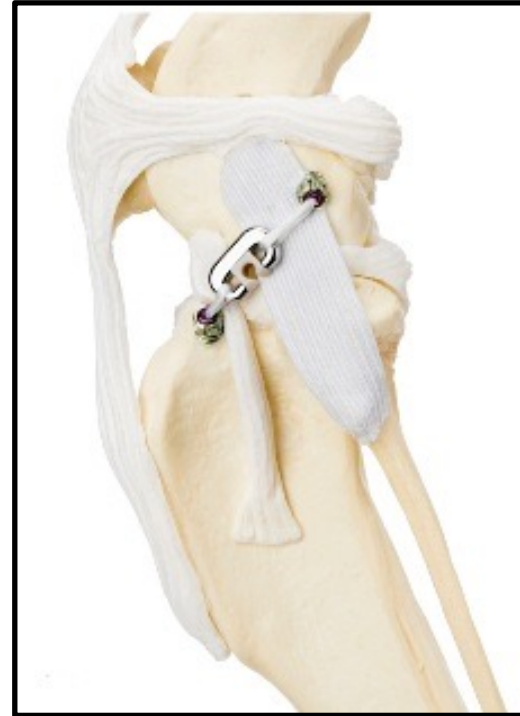- Suture maintains stifle alignment temporarily
- Periarticular fibrosis maintains stability long term
- Several variations/modifications



EXTRACAPSULAR REPAIRS



Tightrope (Arthrex)

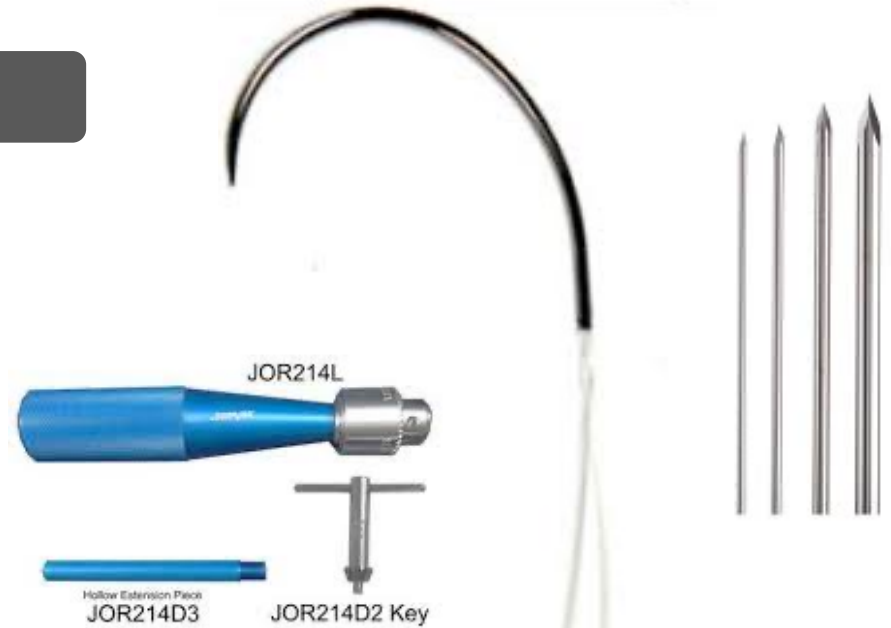


RUBY system (Kyon)

EXTRACAPSULAR REPAIRS

Advantages

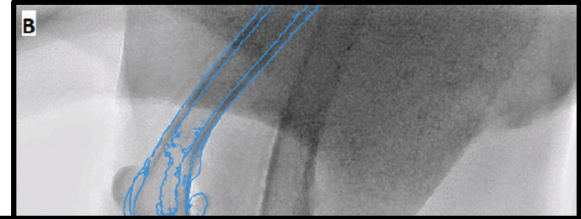
- Attractive option for GP
- No need for specialized implants/equipment
- Less \$\$\$\$
- Less invasive
- Lower infection rates?




EXTRACAPSULAR REPAIRS

Disadvantages

- Inadequately stabilizes joint
- Normal symmetry index not achieved
- Slower return of limb function vs TPLO
- Worse OA vs TPLO
- Less effective with high TPA?



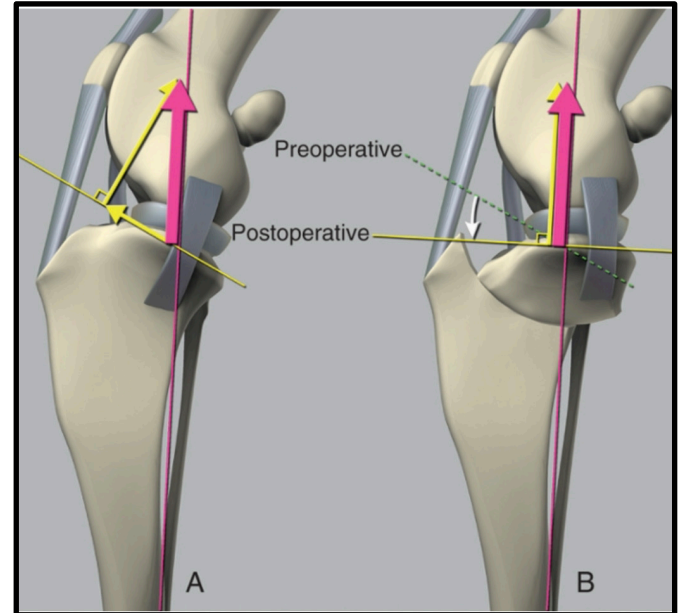
Growing evidence suggests extracapsular techniques less effective than osteotomy procedures

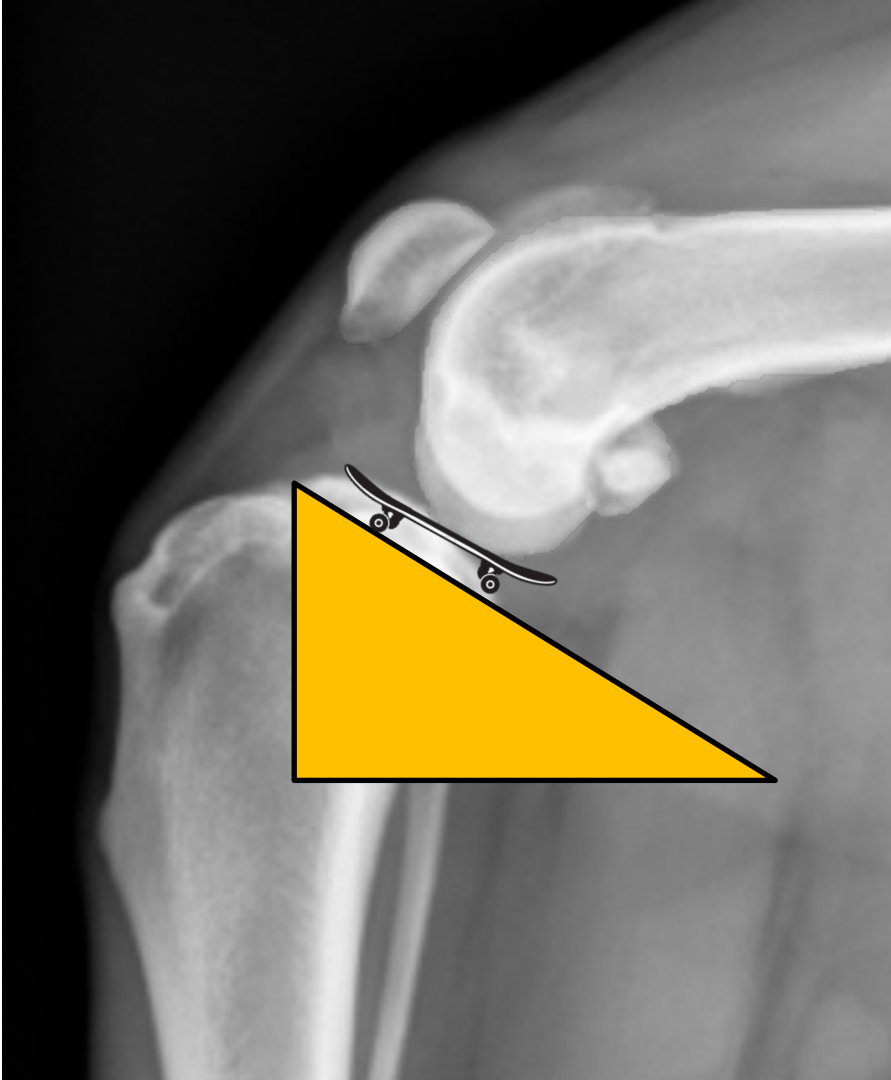


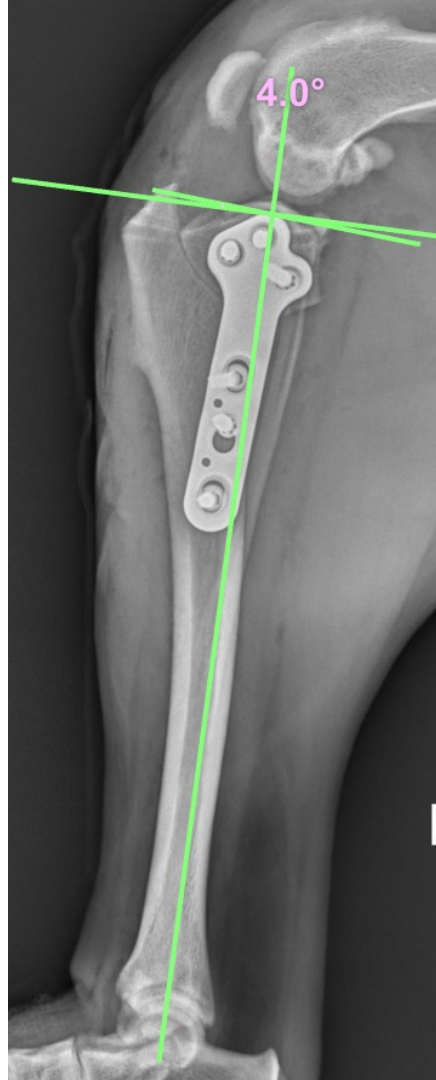
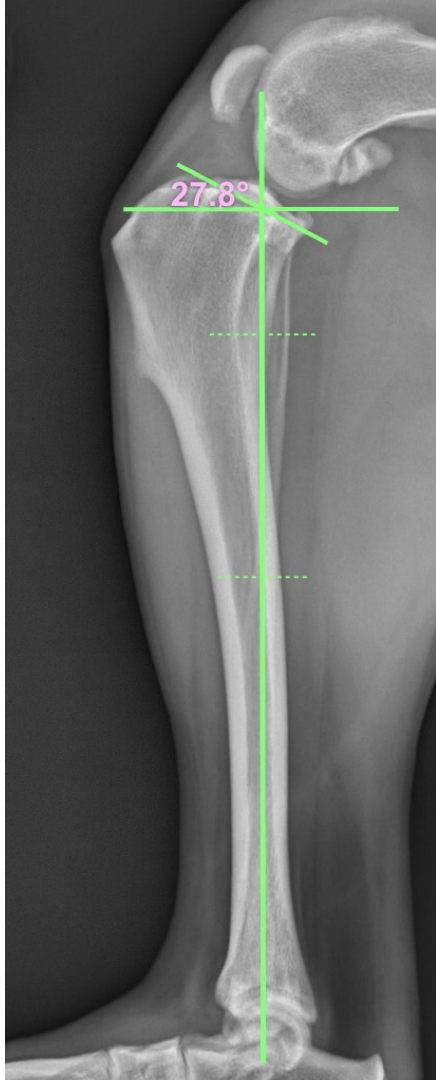OSTEOTOMY PROCEDURES

TPLO

- Tibial thrust primarily due to net force across stifle and tibial plateau angle (TPA)
- Stability restored when TPA perpendicular to net force



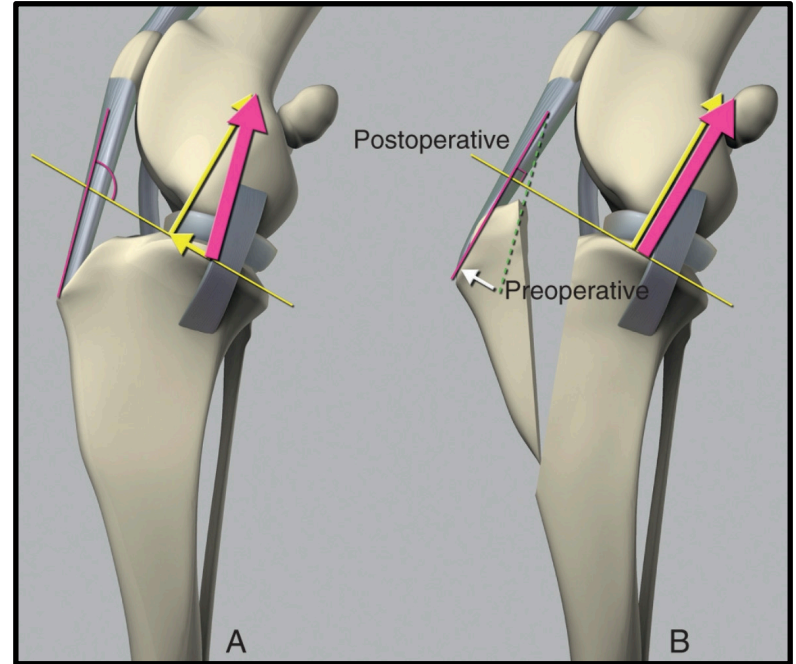


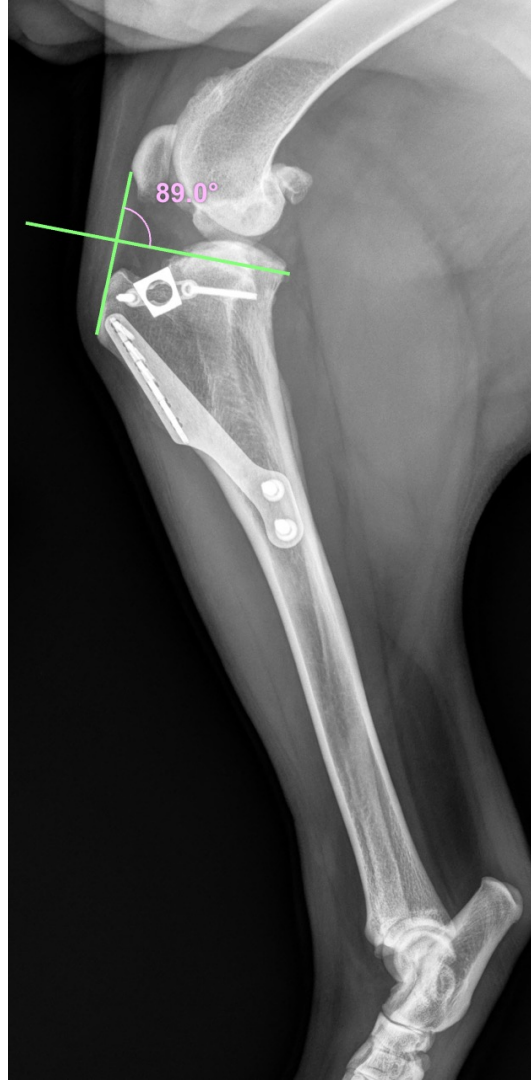
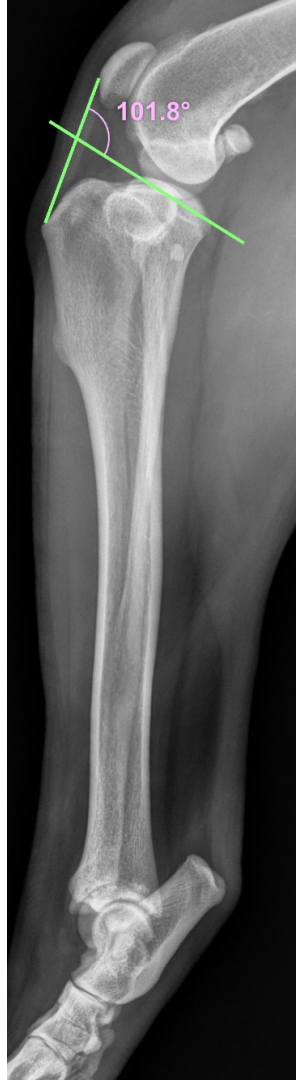

OSTEOTOMY PROCEDURES

TTA

- Tibial thrust primarily due to angle between patellar tendon and tibial plateau
- Advancing tibial tuberosity until patellar tendon perpendicular to tibial plateau eliminates instability



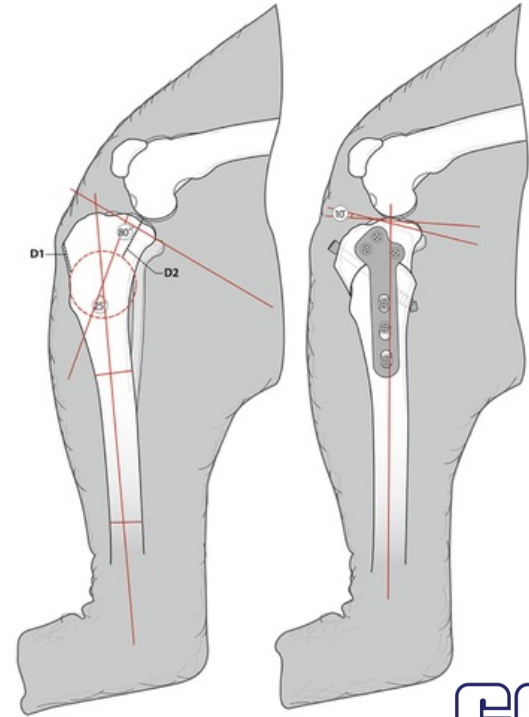


Radiographs courtesy
Dr. Dan Beaver, DVM, DACVS

OSTEOTOMY PROCEDURES

CBLO

- Similar principles as TPLO, TTA
- Natural tibial procurvatum treated as deformity
- Deformity corrected using Paley's laws
- Osteotomy at center of rotation of angulation (CORA)
- **Avoids open physes in juvenile patients**



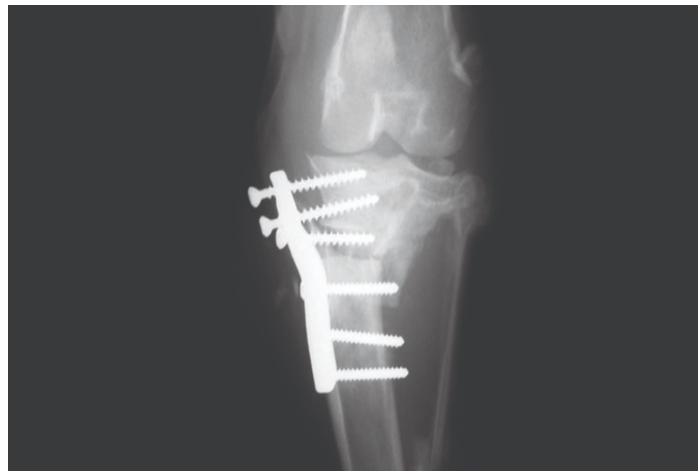OUTCOMES

- 8-12 weeks recovery time
- Strict rest necessary
- Improvement in limb use as early as 1 month
- 90-95% regain full or acceptable limb function
- Progression of OA less than conservative management
- 50-60% contralateral CrCL tear


COMPLICATIONS

- 15% overall for both TTA and TPLO
- 7% infection
- 4% meniscal tear
- Fractures, implant failure – rare
- Patellar tendinosis

NB: variable across studies, % presented from large case series (Fitzpatrick 2010, Costa 2017)




CONCLUDING REMARKS



CrCL disease is a surgical disease



Multimodal management of OA necessary, especially when surgery not an option



Current evidence suggests osteotomy procedures are superior



Prognosis is excellent with surgical intervention

ACKNOWLEDGEMENTS

Kevin Clarke, DVM, DACVS

Jacob Helmick, DVM, DACVS-SA



QUESTIONS?



NOTICE

CE credit certificates & presentation slides will be emailed to you. If you do not receive an email with this information within a week, contact Nichole - *nicholemanfredi@capecodvetspecialists.com*

